

CAT SCRATCH DISEASE CUTANEOUS LESION RESPONSE TO EMPIRIC ANTIBIOTIC TREATMENT: A CASE REPORT

Li-Cheng Chang¹, Nurul N¹ and Keng-Yin Loh²

¹Kuang Community Health Clinic, Selangor; ²Taylor's Clinical School, Selangor, Malaysia

Abstract. We reported the case of a 14-year-old girl who had been scratched by her cat on her forearm 3 days prior to presentation and developed a sudden onset 2 erythematous, circular lesions about 5 cm diameter each with a margin having small weeping vesicles but no purulence. She had some axillary lymphadenopathy. She was diagnosed clinically as having cat scratch disease. No diagnostic confirmatory laboratory testing was available so she was treated empirically with oral azithromycin. The skin lesions resolved completely within 7 days. In resource limited areas where no confirmatory testing is available, patients diagnosed clinically with cat scratch disease may be treated empirically with azithromycin with good results.

Keywords: cat scratch, skin, empirical treatment

Correspondence: Keng-Yin Loh, Taylor's Clinical School, Jalan LGSB Off Jalan Hospital, Sungai Buloh 46000, Malaysia
Tel: +60 12 2373328 E-mail: Kengyin.Loh@taylors.edu.my

INTRODUCTION

Cat scratch disease is caused by a bacterial infection caused by *Bartonella henselae*. *B. henselae* may be found in the saliva and claws of cats and can be spread to humans by a cat scratch, bite or when an infected cat licks the skin of a person with an open wound (Massei *et al*, 2005). Local signs of infection include erythematous skin lesions, papules, pustules, vesicles and regional

lymphadenopathy. Systemic symptoms include fever, lethargy headaches and arthralgia (Klotz *et al*, 2011). Systemic involvement of the liver, spleen, kidneys and eyes had been reported (Wakiguchi *et al*, 2016). More serious complications, such as meningoencephalitis and endocarditis, have also been reported (Wong *et al*, 1995).

We report here a case of clinically diagnosed cat scratch disease treated empirically with azithromycin.

CASE REPORT

A 14-year-old girl from a rural village in Malaysia presented to the community health clinic with a 3-day history of a skin rash after being scratched by her pet cat. She denied any other symptoms, such as fever, headache or arthralgia. Her past medical history was negative for any underlying illness, such as diabetes. On physical examination her temperature was 37°C, her blood pressure was 110/70 mmHg and her pulse was 90 beats/minute. On physical examination she appeared generally healthy and her entire examination was normal except for the following: she had 2 erythematous, oval lesions about 5 cm in diameter on her right forearm just proximal to the wrist (Fig 1). The margin of the rash was raised and there were numerous small weeping vesicles (Fig 2). In the right axilla she had small palpable lymphadenopathy.

The location of the clinic the subject presented to was remote and it was difficult for her to travel to a tertiary hospital for definitive testing to confirm the diagnosis. She was given the clinical diagnosis of cat scratch disease and was treated empirically with oral azithromycin at a dose of 250 mg daily for 7 days. The skin rash resolved completely by 7 days as did the lymphadenopathy (Fig 3). The patient was counselled about cat scratch disease prevention. She was also advised to have the cat checked by a veterinarian and to treat any fleas present.

DISCUSSION

Cat scratch disease, also known as felinosis, can result from cat bites, cat scratches or having an open wound licked by a cat (Klotz *et al*, 2011). Cat scratch disease is caused by an infection with the Gram-negative bacillus *Bartonella henselae*, of which cats are the natural reservoir (Massei *et al*, 2005). This bacterium has been isolated from the blood of infected cats and is transmitted among cats by the cat flea (Windsor, 2001). This bacterium is found in the saliva of infected cats who can spread it to humans by bites, scratches or when a cat licks the open wound of a human (Klotz *et al*, 2011).

Cat scratch disease is more common among children due to their interaction with cats (Klotz *et al*, 2011). The majority of cat scratch disease cases in humans are mild or subclinical (Windsor, 2001). Among the common manifestations are pyrexia and lymphadenopathy. Atypical presentations of cat scratch disease with symptoms of persistent malaise and symptoms mimicking tuberculosis and malignancy have been reported (Weinspach *et al*, 2010). Systemic involvement, such as intrabdominal lymphadenopathy, hepatosplenomegaly and renal lesions has been reported (Wakiguchi *et al*, 2016). Cat scratch disease has also been reported to cause uveitis, retinal vessel occlusion and optic neuropathy (Hobot-Wilner *et al*, 2018). In our patient, there was no systemic involvement.

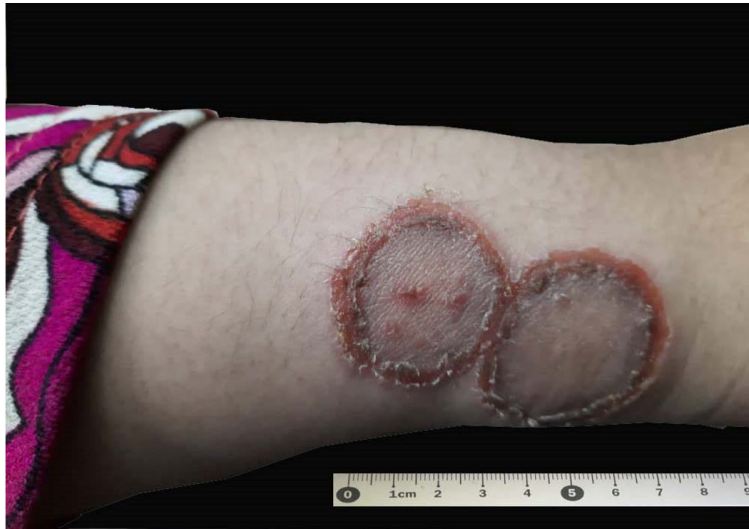

Fig 1 - Two well circumscribed skin lesions on the forearm with raised edges

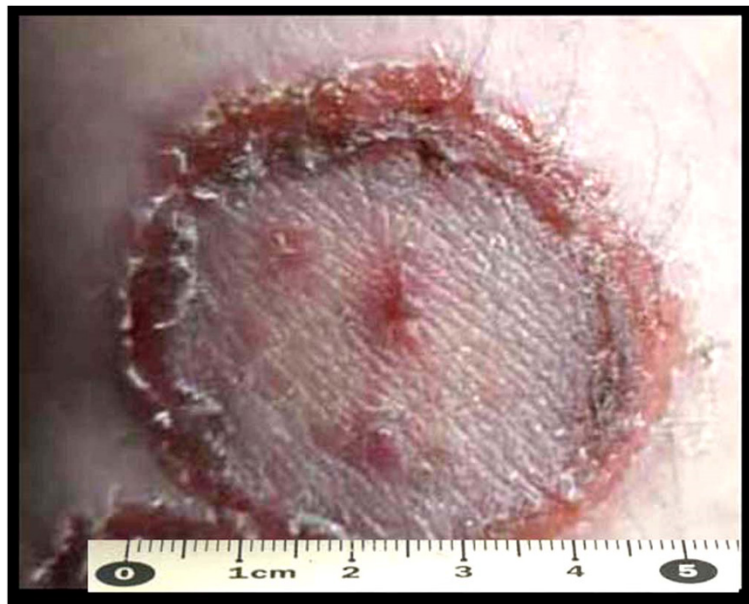

Fig 2 - Close up view showing raised erythematous margin and small vesicles

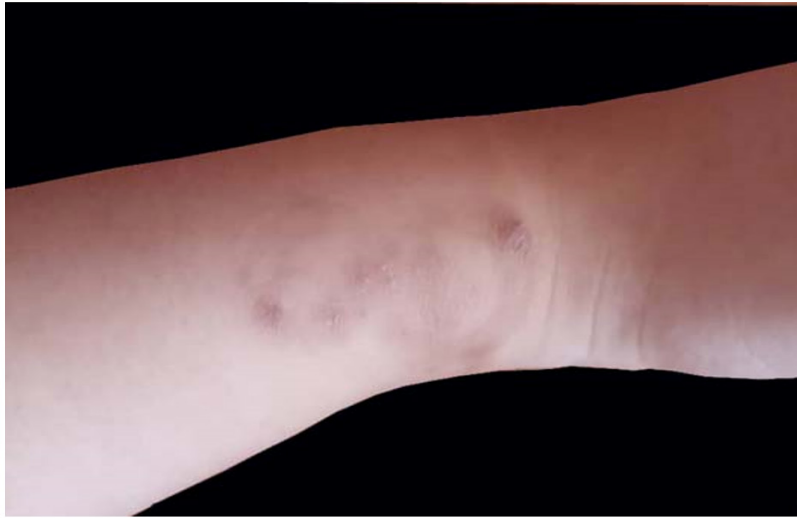


Fig 3 - Seven days after beginning treatment with azithromycin

Cat scratch disease is usually diagnosed by history, physical examination and positive serology for *Bartonella henselae*. Polymerase chain reaction testing has been reported to have a greater sensitivity for diagnosis than serology testing (Eglantin *et al*, 2008). However, laboratory diagnosis may not be available in many places and the diagnosis is clinical as occurred in this case.

Bartonella henselae has been reported to be treated by several types of antibiotics including penicillins, cephalosporins, aminoglycosides, tetracyclines, macrolides and quinolones (Conrad, 2001). Azithromycin treatment of cat scratch disease has been reported to be associated with a shorter duration

of symptoms and more rapid resolution of lymphadenopathy (Bass *et al*, 1998). The patient reported here was treated with azithromycin and the skin lesions have begun to improve by 24 hours and had resolved completely by 7 days.

Preventive education should include personal hygiene, pet hygiene, flea control and veterinarian visits (Klotz *et al*, 2011).

In summary, we reported here a case of cat scratch disease without systemic involvement, diagnosed clinically and treated empirically with azithromycin with complete cure by 7 days. Patient education is important, as is pet care and treatment of fleas. Serious systemic involvement may occur with this disease.

REFERENCES

- Bass JW, Freitas BC, Freitas AD, *et al.* Prospective randomized double blind placebo-controlled evaluation of azithromycin for treatment of cat-scratch disease. *Pediatr Infect Dis J* 1998; 17: 447-52.
- Conrad DA. Treatment of cat-scratch disease. *Curr Opin Pediatr* 2001; 13: 56-9.
- Eglantin F, Hamdad F, El Samad Y, *et al.* The diagnosis of cat-scratch-disease-associated adenitis: diagnostic value of serology and polymerase chain reaction. *Pathol Biol (Paris)* 2008; 56: 461-6. [in French]
- Habot-Wilner Z, Trivizki O, Goldstein M, *et al.* Cat-scratch disease: ocular manifestations and treatment outcome. *Acta Ophthalmol* 2018; 96: e524-32.
- Klotz SA, Ianas V, Elliott SP. Cat-scratch disease. *Am Fam Physician* 2011; 83: 152-5.
- Massei F, Gori L, Macchia P, Maggiore G. The expanded spectrum of bartonellosis in children. *Infect Dis Clin North Am* 2005; 19: 691-711.
- Wakiguchi H, Okamoto Y, Matsunaga M, *et al.* Multiple renal and splenic lesions in cat scratch disease. *Jpn J Infect Dis* 2016; 69: 424-5.
- Weinspach S, Tenenbaum T, Schönberger S, *et al.* Cat scratch disease--heterogeneous in clinical presentation: five unusual cases of an infection caused by *Bartonella henselae*. *Klin Padiatr* 2010; 222: 73-8.
- Windsor JJ. Cat-scratch disease: epidemiology, aetiology and treatment. *Br J Biomed Sci* 2001; 58: 101-10.
- Wong MT, Dolan MJ, Lattuada CP Jr, *et al.* Neuroretinitis, aseptic meningitis, and lymphadenitis associated with *Bartonella (Rochalimaea) henselae* infection in immunocompetent patients and patients infected with human immunodeficiency virus type 1. *Clin Infect Dis* 1995; 21: 352-60.